

Sacroiliac Joint Pain after Lumbo-Sacral Fusion: Incidence and Management Modalities.

Walid K Abouzeid,¹ MD, Hytham M. Ali²

1. Neurosurgery Department, Sohag University hospital, Sohag, Egypt.

2. Anesthesiology Department, Sohag University hospital, Sohag, Egypt.

Abstract

Background Data:

Incidence of sacroiliac dysfunction in a population suffering from low back pain (LBP) after lumbosacral (LS) fusion is unknown. The underlying pathophysiology of SIJ pain may be increased by mechanical load, iliac crest bone grafting, or a misdiagnosis of SIJ syndrome.

Purpose:

To evaluate the incidence of SIJ pain and the accuracy of diagnostic tools with utility of different therapeutic modalities after lumbosacral fusion.

Study design:

A prospective case series study.

Patients and Methods:

We prospectively studied all the patients operated with postero-lateral fusion for the incidence and management of pain originating from SIJ joint in Neurosurgery Department, Sohag University including insurance and private cases between December 2011 and December 2015. The total number of patients was 205 patients. Indications, levels, techniques of fusion, and Postoperative course (improvement of symptoms, and complications such as infection, pseudoarthrosis, metal failure, adjacent segment diseases) all were assessed. Inclusion and exclusion parameters were selected. In addition. Two management modalities were addressed.

Results:

Out of 205 patients, 21 patients (10%) missed in follow up, 117 patients (57%) revealed complete clinical improvement in their manifestations, while 67 patients (32.6%) revealed postoperative pain. 67 patients (32.6%) revealed postoperative pain, (low back pain only in 12 patients 20%, lower limb pain only in 9 patients 13.5%, and both in 46 patients 66.5%). 44 patients who form the basis for this report. Nine patients (20.5%) improved by medical treatment. Thirty-five patients (79.5%) improved by local injection of glucocorticoids, and local anesthetic.

Conclusion:

SLJ pain should be considered at any patient developed low back pain below the waist and gluteal pain with or without nonspecific leg or groin pain in patients after lumbosacral fusion.

Keywords:

Sacroiliac joint, Lumbosacral, Fusion, back pain, medical treatment, local injection.

Introduction

The sacroiliac joint (SIJ) has been implicated by many authors in 10% to 27% as a source of chronic low back, lower extremity pain, gluteal pain, and foot pain.^{19,22} Incidence of sacroiliac dysfunction in a population suffering from low back pain (LBP) after lumbosacral (LS) fusion is unknown^{9,15}. The underlying pathophysiology of SIJ pain may be increased by mechanical load, iliac crest bone grafting, or a misdiagnosis of SIJ syndrome. The problem might be even more complicated because there are no accurate historical, physical, or radiological criteria that can definitively establish a diagnosis of SIJ dysfunction.¹⁹ SIJ may be addressed as a source of persistent pain after lumbosacral fusion that might be due to synovitis, although extra-articular sources of SIJ pain, such as (ligamentous, tendinous, fascial attachment and other cumulative soft tissue injuries) may be suggested.^{8,19}

From the anatomical point of view, SIJ has a unique characteristic not typically found in other diarthrodial joints. First, it looks like the human ear in shape. Second, the SIJ has fibrocartilage, hyaline cartilage in addition to discontinuity of the posterior capsule. Rather than being smooth, the articular surfaces have many ridges and depressions that minimize movement and enhance stability. However, it is attributed to the many adjacent ligaments, and myofascial structures that influence movement and stability.^{5,10,16}

Although Complex innervations of the nerve filaments to the joint are derived from the ventral rami of L4 and L5, the dorsal rami of L5, S1, the ventral ramus of S2 or branches from the ventral rami of the sacral plexus, and the superior gluteal nerve,¹⁶ but also many other reporters considered that still unclear.^{5,10}

Different modalities in management of painful SIJ was addressed by reporters such as conservative management which include medical treatment, pelvic belts, physical therapy, Intra-articular injections with steroids and local anesthetics, prolotherapy and radiofrequency neurotomy have also been used to treat SIJ pain. Although neuro augmentation has also been reported, it is not a common procedure and, surgical options include open arthrodesis which can be achieved anteriorly or posteriorly and, recently, minimally invasive surgery, or percutaneous sacroiliac procedure has also been reported.¹⁶

This study was designed to evaluate the incidence of SIJ pain and the accuracy of diagnostic tools with utility of different therapeutic modalities after lumbosacral fusion.

Patients and Methods

We prospectively studied all the patients operated with postero-lateral fusion for the incidence and management of pain originating from SIJ joint in Neurosurgery Department, Sohag University between December 2011 and December 2015. The total number of patients was 205 patients. Indications, levels, techniques of fusion, and Postoperative course (improvement of symptoms, and complications such as infection, pseudoarthrosis, metal failure, adjacent segment diseases) all were assessed.

Patients included in the current study are those who reported pain below the L5, over the posterior aspect of one or both SIJs, with or without leg pain, and with a distribution compatible with an SIJ origin after lumbosacral fusion.²

Severely uncontrolled DM, Previously locally injected patients, either epidurally or locally at SIJ, Severely osteoporotic or osteopenic patients, Medically diseased such as (ankylosing spondylitis, reactive arthritis, psoriatic arthritis, or enteropathic arthritis), Iliac crest grafted patients, More than 1 spinal operation, or more than 2 trial for screws insertion, long segment fixation (not more than 5 level), Extremities of age, more than 75 years old, or very young below 18 years old, Previously operated patients outside our hospital with no clear case scenario, Psychologically diseased patient, Marked obese patient with body mass index > 40%, and Systemic disease like coagulopathy, known allergic to any drugs, or systemic tumor were excluded from this study.

All patients were subjected to clinical and radiological assessment. Full medical history assessment, and detailed physical examination including Patrick's test, the compression test, and sacral sulcus tenderness.⁷

Clinically suspected patients (patients who exhibited pain upon application of Patrick's test, the compression test, and sacral sulcus tenderness) received the following imaging studies: Plain X ray pre, and postoperative lumbosacral (LS) (antero-posterior AP, Lateral, full flexion, extension, and oblique views), Plain X ray pelvic (AP, and lateral), and MRI or CT (LS, SIJ) according to each case clinically.

Two main approaches (medical and local injection) were used to manage our patients, after detailed explanation of each approach, the expected time of improvement, and the technique.

❖ ***A-Medically treated:***

Via Strong NSAID (systemic and local), muscle relaxant, physiotherapy, pelvic stabilization exercises to allow dynamic postural control, and muscle balancing of the trunk and lower extremities with rest for 1-3 weeks, for three consecutive months.

❖ ***B-Local injection:***

By neurosurgeon, and anesthesiologist, the patient was placed in the prone position, and the sacroiliac skin was prepared and draped. With the C-arm tube perpendicular to the table, the skin over the inferior margin of the SIJ was marked. The tube was adjusted slightly as necessary until the entrance to the SIJ, plus locally tender points by patients' examinations was clearly visible. A 23-gauge 3.5-inch spinal needle was then inserted into the entrance. Then, 1 ml of 0.5% bupivacaine (or 2% lidocaine) mixed with 1 ml (40 mg) of Depo-Medrol was injected into the SIJ.

In our study we categorized the locally injected patients to 3 main groups (with 2 subgroups in each), according to onset of improvement, percentage of improvement from the original pain, and maintenance of improvement after injection by detailed explanation to the patients.

We applied visual analogue score (VAS) to address pain improvement in medically treated group, and classified into three categories of score by detailed explanation to the patients.

Results

❖ ***Demographic Data:***

Out of 205 patients, 21 patients(10%) missed in follow up, 117 patients (57%) revealed complete clinical improvement in their manifestations, while 67 patients (32.6%) revealed postoperative pain, (low back pain only in 12 patients 20%, lower limb pain only in 9 patients 13.5%, and both in 46 patients 66.5%)(Figure 1).

By application of the history, clinical, radiological assessment, and exclusion criteria, SIJ was suspected to be the source of pain in 44 patients who form the basis for this report. Incidence of SIJ pain after Postrolateral (PL) fusion was 21.5% in our study group (44 patients out of total 205).

There were 18 men (41%) and 26 women (59%). The mean age was 50 years (range 20–73 years)(Table 1).The average time from lumbosacral fusion till pain appearance was ranged from (1 month- 4 years)(Table 2). There were nineteen patients (43%) who underwent one-level fusion at L5–S1, seventeen patients (38.5%) who had fusions from L4 to the sacrum, and eight patients (18%) with lumbosacral fusions above L4(Table 3). Body mass index (BMI) ranged from 18 to 35.2% in males, and from 16.4 to 39.6% in females (Figure 2).

❖ ***Location, Pain pattern, and Management:***

Pain predominantly located unilaterally in thirty-three cases (75%) with slight clear shift to right side (n=18) over the left side (n=14), and bilaterally in rest of the patients (n=12).

According to the pain pattern distributions: The buttock (94%), Lower lumbar region (72%), Lower extremity only (50%), below the knee (28%), Groin area (14%), Foot pain (12%), Upper lumbar lesion (6%), and Abdominal pain (2%) (Table 4).

❖ **Protocol:**

Our protocol was conservative management should be applied for all cases first for 3 consecutive months, after that we tried local injection approach.

Nine patients (20.5%) improved by medical treatment. Thirty-five patients (79.5%) improved by local injection of glucocorticoids, and local anesthetic. According to the trials of injection, thirteen revealed complete improvement after single injection (37.3%), nineteen patients need twice trial injection (54.2%), in distance between (2 weeks-3 months) and three patients only need more adjuvant therapy (8.5%), (2 cases need 3rd trial injection in addition to medical treatment, and only one patient improved after 3rd trial of injection without need for other medications).(Figure 3)

❖ **Radiographic Studies:**

Using CT scans. A diagnosis of SIJ degeneration could be slightly made in 21 cases (47.7%) on the basis of the presence of non-specific findings such as sclerosis, osteophytes, and narrowing of the joint space, and negative in the rest of the patients.

MRI 1.5 tesla no additional finding from CT except T2-weighted images showed early marrow edema better⁸ in 3 cases (8.5%). Plain X-ray LS just revealed straightening of lordotic curve in 18 cases (41%), otherwise all other investigations were insignificant.

❖ **Change in Pain Character in Locally Injected Group:(Figure 4)**

* **Group 1: (n=20) cases (57%)**

A-Pain relief within 30-90 minutes, >50% improvement, and prolonged > 30 days (11 case)

B- Pain relief within 30-90 minutes, >50%, improvement and prolonged < 30 days (9cases)

* **Group 2: (n=13) cases (37%)**

A-Pain relief within 30-90 minutes, <50%, improvement and prolonged > 30 days (8 cases)

B- Pain relief within 30-90 minutes, <50%, improvement and prolonged <30 days (5 cases)

* **Group 3: (n=2) cases (5%)**

A-No Pain relief within 30-90 minutes, but <50%, improvement and prolonged < 30 days (2 cases)

B- No any response, or even delayed improvement at all (none)

❖ **VAS was Classified into:(Figure 5)**

* **Group I**

(score 1-3) in 7 cases (77.8%) in which pain improved totally after the three months with no need to continue other medication.

* **Group II**

(score 4-6) in one case (11.1%) in which pain improved totally after the 3 months with mild pain recurrence, with simple need to continue other medication for less than 1 month.

* **Group III**

(score >7) in one case (11.1%) in which pain improved totally after the 3 months with pain recurrence, but marked need to continue other medication for more than 1-3 months., but no any other interventions.

Table 1.Age of the patients

Age group	Number
< 25 years	3
26-36 years	9
37-50 years	17
51-70 years	11
> 70 years	4

Table 2.Average time from fusion to pain appearance

Time	Number
1 week – 3 months	3
3-6 months	9
6 months – 1 year	14
1-2 years	13
> 2 years	5

Table 3. Level of fusion

Level	Number
L5-S1	17(39.9%)
L4-S1	19(41.9%)
Above L4	8(18.2%)

Table 4. Pain pattern

Pain site	Number
Buttock	94%
Lower lumbar region	72%
Lower extremities only	50%
Below the knee	28%
Groin area	14%
Foot pain	12%
Upper limb region	6%
Abdomen	2%

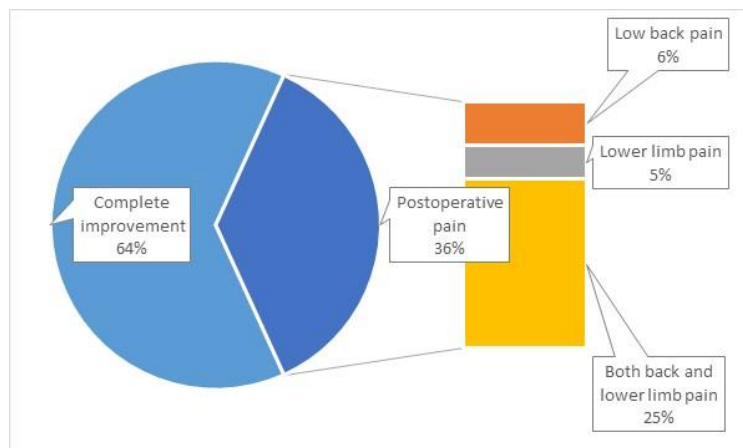


Figure 1. Improvement of patients

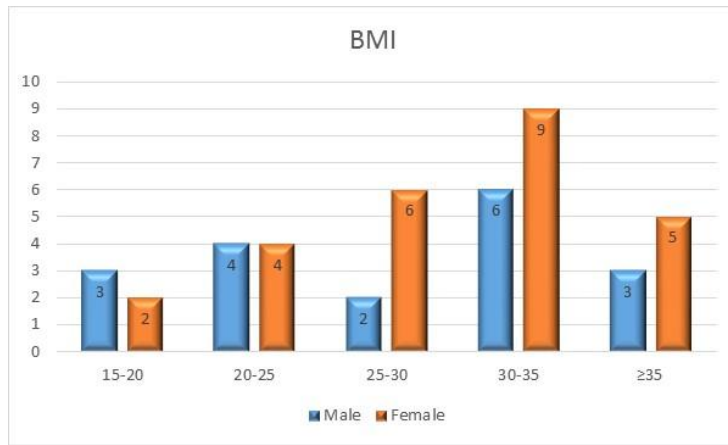


Figure 2. Body mass index

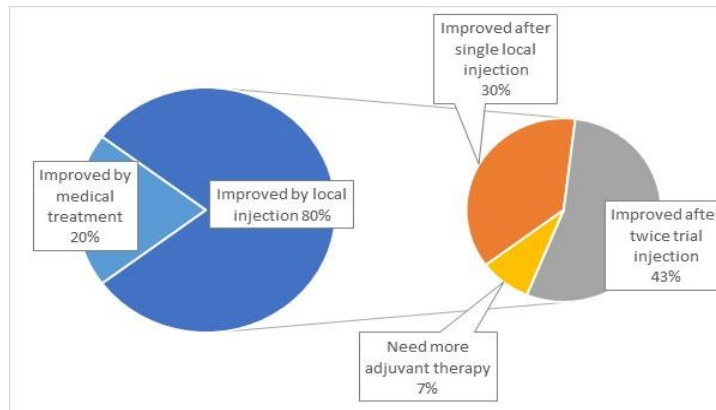


Figure 3. Outcome of treatment modalities

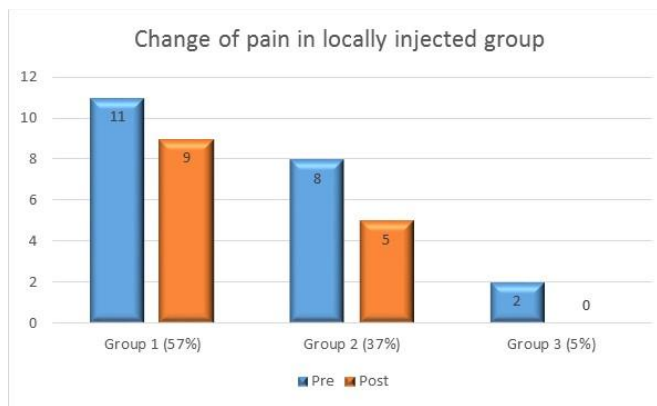


Figure 4. Change of pain in locally injected group

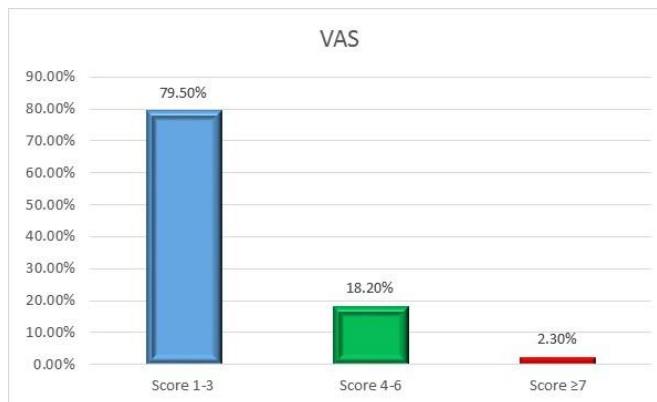


Figure 5. VAS

Discussion

Developing low back pain, gluteal, groin, leg or foot pain in patients who have had a lumbar fusion to the sacrum, take the spine surgeon attention to radicular syndrome, facet syndrome, discogenic syndrome, discitis, or even FBSS as spine surgeons are very familiar with these diagnoses. However, painful SIJ dysfunction may not be as familiar and therefore may not be considered in patients with pain after lumbosacral fusion.^{22,23}

Although Our study strongly suggests that the SIJ plays a role in pain persisting after lumbar fusion, that proved by Maigne et al¹⁹ but also other structures such as the iliolumbar ligament or piriformis muscle cannot be excluded as potential sources of pain because they are functionally related⁶ which is not clear in our study, or even most of the previous reporters. by accurate examination and negative radiological findings.

Most of the previous studies^{3,20} revealed unilateral SIJ pain more frequently (76%) than bilaterally (24%), which nearly the same incidence in our study by 70.5%, and 29.5%; respectively. Several hypotheses were suggested to explain the cause of SIJ pain in patients who have undergone lumbar fusion.^{17,19} These hypotheses include: (1) the transfer of a mechanical load after the surgery on the SIJ, as a consequence of straightening of the fused lumbar segments, and load transfer on the disc above the fused level, the disc below the fused, and adjacent mobile segments is also subjected to new strains. In addition to and increase stress on the adjacent facet that finally lead to transfer of motion from the fused segment to the next mobile intact segment, this mostly accepted in our study.² (2) Disruption of the SIJ following bone graft harvesting donor site pain was proposed by Frymoyer et al,¹¹⁻¹⁴ Ectopic bone formation at the graft site was also proposed. Patients who received iliac bone grafting were excluded from the current study. (3) Misdiagnosis of SIJ pain as a cause of pre-fusion low back pain. This possibility was excluded in our patients by meticulous check of pre-operative history, physical, and radiological studies in addition to exclusion of fusions performed in other hospitals. (4) Some studies suggested accelerated degeneration, that would be anticipated to be more with the greater the number of fused segments, therefore we excluded the long segment fixation from our study group. (5) Extension of the fusion to the sacrum, was addressed by numerous clinical and experimental studies to explain the role of adjacent segment disease that should increase mobility in the cephalic and/or caudal directions.

Extensive literatures reported the magnitude of the sacrum angular motion and average of stresses across SIJ articular surfaces after lumbosacral fusion were compared with intact model in flexion, extension, lateral bending, and axial rotation motions which finally conclude that lumbar fusion leads to increases in angular motion and stress across sacroiliac joint.^{1,11}

Iatrogenic injury to the joint itself or other local nerves, considered a potential cause of SIJ pain after lumbosacral fusion which was excluded via repeated screw insertion trails or operations. In very rare cases, SIJ pain may be caused by hardware. For example, Ahn and Lee¹ reported iatrogenic SIJ syndrome caused by the screw head and rod of percutaneous pedicle screw fixation at the L5–S1 level.

Also, sharp rod tip and the laterally located screw head may irritate the iliac crest and distract the SIJ, leading to intractable SIJ pain. This possibility was also excluded in our patients as we used top loading system. Elgafy et al,⁹ found that abnormal CT findings, in 63.5% % in their study, and Ha et al.¹⁵ reported positive results from CT scans in 38.2 % of patients, but in our series nearly 47.7% showed positive SIJ findings in CT. The efficacy of SPECT in evaluating postoperative SLJ pain was reported because it can identify specific bony abnormalities in patients with complex problems, the evidence of SIJ dysfunction in patients with spine surgery followed by LBP was obtained also after single photon emission computed tomography (PET) and bone scintigraphy⁷. Results have shown significantly increased uptake in SIJ, which might reflect mechanical overloading and SLJ pain. In our study we never performed the previously mentioned investigations.

Katz et al,¹⁷ on 34 patient, Maigne et al,¹⁹ on 61 patient, DePalma et al,⁷ on 28 patient and Liliang et al,¹⁸ on 130 patient revealed multiple clinical studies of diagnostic injection for sacroiliac joint pain after lumbar/lumbosacral fusion, but in our study we performed injection as diagnostic, and therapeutic purpose.

In our study we found that more than half (57%) of our patients showed fast onset improvement after local injection. That mostly due to local anesthetic effect, and nearly 95% of all patient revealed satisfactory improvement due to steroid phase which mostly reported by other authors.^{7,18}

There is wide range in delineating the role of SIJ in failed back surgery syndrome (FBSS) from 4.7% to 18% in many series^{2,3,17}, but in our case study we feel the incidence (21.5%) is slightly higher than all the previous reporters which mean that we need more studies and focusing upon SIJ behavior.

However, detailed history, consistent clinical findings, the excellent response to either medical, or local treatment, with insignificant radiological findings were collectively support that our diagnosis was correct.

Conclusion

SLJ pain should be considered at any patient developed low back pain below the waist and gluteal pain with or without nonspecific leg or groin pain in patients after lumbosacral fusion.

Contribution of SIJ pain as a possible cause of FBSS might be higher than expected.

Clinical and radiological assessment raises a high index of suspicion of SLJ as a source of pain after lumbosacral fusion.

At many instances, the diagnosis is truly made based on exclusion of other possible causes.

Although Local injection considered the golden approach in diagnosis, and treatment, but also medical treatment should be attempted first for at least three consecutive months.

References

- 1) Ahn Y, Lee SH: Iatrogenic sacroiliac joint syndrome after percutaneous pedicle screw fixation at the L5-S1 level: case report. *Neurosurgery* 67(3):E865-6; discussion E6, 2010
- 2) Bastian L, Lange U, Knop C, Tusch G, Blauth M: Evaluation of the mobility of adjacent segments after posterior thoracolumbar fixation: a biomechanical study. *European spine journal: official publication of the European Spine Society, the European Spinal Deformity Society, and the European Section of the Cervical Spine Research Society* 10(4):295-300, 2001
- 3) Benzon HT, Katz JA, Benzon HA, Iqbal MS: Piriformis syndrome: anatomic considerations, a new injection technique, and a review of the literature. *Anesthesiology* 98(6):1442-8, 2003
- 4) Bredella MA, Steinbach LS, Morgan S, Ward M, Davis JC: MRI of the sacroiliac joints in patients with moderate to severe ankylosing spondylitis. *AJR American journal of roentgenology* 187(6):1420-6, 2006
- 5) Brooke R: The Sacro-Iliac Joint. *Journal of anatomy* 58(Pt 4):299-305, 1924
- 6) Chow DH, Luk KD, Evans JH, Leong JC: Effects of short anterior lumbar interbody fusion on biomechanics of neighboring unfused segments. *Spine* 21(5):549-55, 1996
- 7) DePalma MJ, Ketchum JM, Saullo TR: Etiology of chronic low back pain in patients having undergone lumbar fusion. *Pain medicine* 12(5):732-9, 2011
- 8) Ebraheim NA, Elgafy H, Semaan HB: Computed tomographic findings in patients with persistent sacroiliac pain after posterior iliac graft harvesting. *Spine* 25(16): 2047-51, 2000
- 9) Elgafy H, Semaan HB, Ebraheim NA, Coombs RJ: Computed tomography findings in patients with sacroiliac pain. *Clinical orthopaedics and related research* 382:112-8, 2001
- 10) Fortin JD, Falco FJ: The Fortin finger test: an indicator of sacroiliac pain. *American journal of orthopedics* 26(7):477-80, 1997
- 11) Frymoyer JW, Hanley E, Howe J, Kuhlmann D, Matteri R: Disc excision and spine fusion in the management of lumbar disc disease. A minimum ten-year followup. *Spine* 3(1):1-6, 1978
- 12) Frymoyer JW, Howe J, Kuhlmann D. The long-term effects of spinal fusion on the sacroiliac joints and ilium. *Clinical orthopaedics and related research* 134:196-201, 1978
- 13) Frymoyer JW, Matteri RE, Hanley EN, Kuhlmann D, Howe J: Failed lumbar disc surgery requiring second operation. A long-term follow-up study. *Spine* 3(1):7-11, 1978
- 14) Frymoyer JW, Pope MH: The role of trauma in low back pain: a review. *The Journal of trauma* 18(9):628-34, 1978
- 15) Ha KY, Lee JS, Kim KW: Degeneration of sacroiliac joint after instrumented lumbar or lumbosacral fusion: a prospective cohort study over five-year follow-up. *Spine* 33(11):1192-8, 2008
- 16) Hansen HC, McKenzie-Brown AM, Cohen SP, Swicegood JR, Colson JD, Manchikanti L: Sacroiliac joint interventions: a systematic review. *Pain physician* 10(1): 165-84, 2007
- 17) Katz V, Schofferman J, Reynolds J: The sacroiliac joint: a potential cause of pain after lumbar fusion to the sacrum. *Journal of spinal disorders & techniques* 16(1):96-9, 2003
- 18) Liliang PC, Lu K, Liang CL, Tsai YD, Wang KW, Chen HJ: Sacroiliac joint pain after lumbar and lumbosacral fusion: findings using dual sacroiliac joint blocks. *Pain Medicine* 12(4): 565-70, 2011
- 19) Maigne JY, Planchon CA: Sacroiliac joint pain after lumbar fusion. A study with anesthetic blocks. *European spine journal: official publication of the European Spine Society, the European Spinal*

Deformity Society, and the European Section of the Cervical Spine Research Society 14(7):654-8, 2005

- 20) Pool-Goudzwaard AL, Kleinrensink GJ, Snijders CJ, Entius C, Stoeckart R: The sacroiliac part of the iliolumbar ligament. *Journal of anatomy* 199(Pt 4):457-63, 2001
- 21) Ross MD, Nordeen MH, Barido M: Test-retest reliability of Patrick's hip range of motion test in healthy college-aged men. *Journal of strength and conditioning research / National Strength & Conditioning Association* 17(1):156-61, 2003
- 22) Slipman CW, Shin CH, Patel RK, Isaac Z, Huston CW, Lipetz JS, et al: Etiologies of failed back surgery syndrome. *Pain medicine* 3(3):200-14; discussion 14-7, 2002
- 23) Waguespack A, Schofferman J, Slosar P, Reynolds J: Etiology of long-term failures of lumbar spine surgery. *Pain medicine* 3(1):18-22, 2002

المخلص العربي

الاختلال الوظيفي في المفصل الحوضي العجزي بعد إجراء جراحة الالتحام القطني العجزي: معدل حدوثه وعلاجه

البيانات الخلفية:

لا يعرف بالضبط معدل حدوث اختلال وظيفي في المفصل الحوضي العجزي في المرضى الذين يعانون من آلام أسفل الظهر بعد إجراء جراحة الالتحام القطني العجزي . ويمكن أن تزداد الأسباب الكامنة وراء الألم الناتج عن المفصل الحوضي العجزي بزيادة الحمل الميكانيكي أو تطعيم الحافة الحرقفية العظيمة أو خطأ في تشخيص متلازمة المفصل الحوضي العجزي.

الهدف:

تقييم حالات الألم الناتجة عن المفصل الحوضي العجزي، ودقة أدوات التشخيص وفائدة الطرائق العلاجية المختلفة بعد إجراء عملية التحام الفقرات القطنية العجزية.

تصميم الدراسة:

دراسة مستقبلية

المرضى والطرق:

تمت دراستنا على المرضى الذين تمت إجراء جراحة التحام قطني عجزي لهم في قسم جراحة الأعصاب بجامعة سوهاج في الفترة ما بين ديسمبر 2011 وديسمبر 2015. وبلغ عدد المرضى 205 مريض.

النتائج:

من 205 مريضا، تغيب 21 مريضا (10%) عن المتابعة بعد الجراحة، وكشفت المتابعة أن 117 مريضا (57%) حدث لهم تحسن سريري كامل، في حين تعرض 67 مريضا (32.07%) لآلام ما بعد الجراحة.

الاستنتاج:

ينبغي توقع حدوث ألم ناتج عن المفصل الحوضي العجزي في أي آلام تقع أسفل ظهر المريض تحت منطقة الخصر والأرداف سواء مع وجود أو عدم وجود آلام في الساقين في مرضى ما بعد جراحة الالتحام القطنية العجزية.